

THE JOURNAL OF BONE & JOINT SURGERY

# J B & J S

*This is an enhanced PDF from The Journal of Bone and Joint Surgery*

*The PDF of the article you requested follows this cover page.*

---

## The Use of Alendronate to Prevent Early Collapse of the Femoral Head in Patients with Nontraumatic Osteonecrosis. A Randomized Clinical Study

Kuo-An Lai, Wun-Jer Shen, Chyun-Yu Yang, Chung-Jung Shao, Jui-Ting Hsu and Ruey-Mo Lin  
*J. Bone Joint Surg. Am.* 87:2155-2159, 2005. doi:10.2106/JBJS.D.02959

---

**This information is current as of October 10, 2006**

### Supplementary material

Commentary and Perspective, data tables, additional images, video clips and/or translated abstracts are available for this article. This information can be accessed at <http://www.ejbs.org/cgi/content/full/87/10/2155/DC1>

### Subject Collections

Articles on similar topics can be found in the following collections

[Adult Disease](#) (1317 articles)

[Hip](#) (535 articles)

[Osteonecrosis](#) (63 articles)

[Drug Therapy](#) (92 articles)

### Reprints and Permissions

Click here to [order reprints or request permission](#) to use material from this article, or locate the article citation on [jbjs.org](http://www.jbjs.org) and click on the [Reprints and Permissions] link.

### Publisher Information

The Journal of Bone and Joint Surgery  
20 Pickering Street, Needham, MA 02492-3157  
[www.jbjs.org](http://www.jbjs.org)

# THE USE OF ALENDRONATE TO PREVENT EARLY COLLAPSE OF THE FEMORAL HEAD IN PATIENTS WITH NONTRAUMATIC OSTEONECROSIS

## A RANDOMIZED CLINICAL STUDY

BY KUO-AN LAI, MD, WUN-JER SHEN, MD, CHYUN-YU YANG, MD,  
CHUNG-JUNG SHAO, MD, JUI-TING HSU, PHD, AND RUEY-MO LIN, MD

*Investigation performed at the Orthopaedic Department, National Cheng Kung University Medical Center, Tainan, Taiwan*

**Background:** Osteonecrosis of the femoral head is the most common diagnosis leading to total hip arthroplasty in young adults. Joint-preserving treatment options have been mainly surgical, with inconsistent results. Alendronate (a bisphosphonate agent) has been shown to lower the prevalence of vertebral compression fractures and could potentially retard the collapse of an osteonecrotic femoral head. The purpose of this study was to test the effect of alendronate in preventing early collapse of the femoral head in patients with nontraumatic osteonecrosis.

**Methods:** Forty patients with Steinberg stage-II or III nontraumatic osteonecrosis of the femoral head and a necrotic area of >30% (class C) were randomly divided into alendronate and control groups of twenty patients each. Patients in the alendronate group took 70 mg of alendronate orally per week for twenty-five weeks, while the patients in the control group did not receive this medication or a placebo. The patients were observed for a minimum of twenty-four months. Harris hip scores, plain radiographs, and magnetic resonance imaging scans were obtained.

**Results:** During the study period, only two of twenty-nine femoral heads in the alendronate group collapsed, whereas nineteen of twenty-five femoral heads in the control group collapsed ( $p < 0.001$ ). One hip in the alendronate group underwent total hip arthroplasty, whereas sixteen hips in the control group underwent total hip arthroplasty ( $p < 0.001$ ).

**Conclusions:** Alendronate appeared to prevent early collapse of the femoral head in the hips with Steinberg stage-II or IIIC nontraumatic osteonecrosis. A longer duration of follow-up is needed to confirm whether alendronate prevents or only retards collapse.

**Level of Evidence:** Therapeutic Level I. See Instructions to Authors for a complete description of levels of evidence.

End-stage degenerative arthritis caused by osteonecrosis of the femoral head accounts for approximately 10% of the primary total hip arthroplasties performed in the United States<sup>1</sup> and for approximately 45% of the primary total hip arthroplasties done in Taiwan<sup>2</sup>. Without treatment, >70% of femoral heads with osteonecrosis collapse and require prosthetic replacement within three to four years of diagnosis<sup>3</sup>. Many joint-preserving treatments, including hyperbaric oxygen, high-energy shock wave, electrical stimulation, core decompression, vascularized bone graft, and various osteotomies,

have been developed in an effort to preserve the osteonecrotic femoral head in a precollapse stage<sup>4-12</sup>. Unfortunately, the success rates of all of these treatments vary widely, and there is no universally accepted treatment<sup>13</sup>.

Pharmacologic treatment of osteonecrosis remains very limited. Cui et al. demonstrated the effectiveness of antilipid agents in treating steroid-induced osteonecrosis in a chicken model<sup>14</sup>, and Pritchett found that statins were effective in humans receiving steroids<sup>15</sup>. Although osteonecrosis is the result of various conditions, the common final pathway leading to collapse of the femoral head is an uncoupling of the rates of osteoclastic bone resorption and osteoblastic bone regeneration. We reasoned that by inhibiting the activity of the osteoclasts, collapse of the femoral head might be delayed or even



A commentary is available with the electronic versions of this article, on our web site ([www.jbjs.org](http://www.jbjs.org)) and on our quarterly CD-ROM (call our subscription department, at 781-449-9780, to order the CD-ROM).

prevented. Alendronate, a bisphosphonate, reduces osteoclast activity and inhibits bone turnover<sup>16</sup>. It is widely used in the treatment of osteoporosis and has been shown to decrease the prevalence of vertebral compression fractures<sup>17</sup>. The goal of this prospective study was to determine whether alendronate could delay or prevent the progression of osteonecrosis.

### Materials and Methods

The majority of our patients with osteonecrosis of the femoral head initially present with Steinberg stage-II or III osteonecrosis<sup>18</sup> (see Appendix). These are also the stages in which the treatment strategies are most varied, so we focused on this subgroup. Inclusion criteria for this study consisted of nontraumatic osteonecrosis of one or both femoral heads, Steinberg stage-II or III osteonecrosis, a necrotic area of >30% (a class-C lesion)<sup>19</sup>, and no previous treatment of the femoral head. In patients in whom only one femoral head met the inclusion criteria, the status of the contralateral side (normal, collapsed, previous treatment with a hip arthroplasty, etc.) was noted. Specific diagnoses, if any, and known risk factors associated with osteonecrosis were noted, along with all medications taken.

This study was approved by our institutional human experiment and ethics committee. All patients consented to participate in this study. Patients were informed regarding other treatment options and their possible outcomes. They were allowed to choose these treatments at the beginning of or during the study. Because of national health insurance reimbursement regulations and the lack of a suitable placebo, the patients were not blinded with regard to their treatment group.

From June through October 2002, forty patients were enrolled and randomly assigned to the alendronate group or the control group. The study period ranged from twenty-four to twenty-eight months. The alendronate group consisted of fifteen men (twenty-three hips) and five women (six hips) with a mean age of 42.6 years (range, twenty-two to sixty-five years). Seven of them had a history of glucocorticosteroid intake: one used it for the treatment of systemic lupus erythematosus; one, for nephrotic syndrome; and the others, for allergic conditions. The other thirteen patients reported no history of taking a steroid medication or having a disease related to osteonecrosis. The control group consisted of fifteen men (eighteen hips) and five women (seven hips) with a mean age of 42.4 years (range, twenty to sixty-four years). Six of them had a history of glucocorticosteroid intake: two took it for the treatment of systemic lupus erythematosus and four used it because of allergic conditions. The other fourteen patients had no known diseases and had not taken medications that were related to osteonecrosis. The two groups had similar demographics with regard to etiology, known risk factors, and other medications. The initial evaluation included anteroposterior radiographs of the pelvis with the hips in neutral position and in a position of abduction and external rotation (the so-called frog-leg view), magnetic resonance imaging of the hips, and a clinical evaluation with use of the Harris hip score. All patients were given nonsteroidal anti-inflammatory agents

to take as needed. Daily activities were not restricted. Weight-bearing was not specifically forbidden (since this restriction is impossible to enforce in patients with bilateral involvement), but it was usually avoided by the patient because of pain.

Patients in the alendronate group took 70 mg of Fosamax (alendronate; Merck, Whitehouse Station, New Jersey) orally every week for twenty-five weeks, while the patients in the control group were not given this medication or a placebo. This dosage regimen was chosen because it is the one currently recommended for the treatment of osteoporosis. The patients were followed radiographically every ten weeks. All radiographs were read in a blinded fashion by experienced surgeons not involved in the care of these patients. The indication for total hip arthroplasty was collapse of the femoral head (stage IV or V) with intractable pain, and it was applied uniformly throughout the study. At the time of the last follow-up, or before surgery in those who went on to femoral head collapse, the patients were evaluated with radiographs, the Harris hip score, and magnetic resonance imaging. The results were analyzed with use of the chi-square test. Kaplan-Meier survivorship analysis was done with total hip arthroplasty as the end point of this study. The hips that underwent core decompression at the beginning of or during the study were not excluded in order to retain the integrity of the demographic data.

### Results

#### Commencement of Study

In the control group, the mean Harris hip score at the beginning of the study was 67.6 points (range, 26 to 88 points). Thirteen hips were in stage II, and twelve hips were in stage III. Three hips (all in stage II) underwent core decompression at the beginning of the study. On the contralateral side, three hips had previously been treated with a total hip arthroplasty, four hips were beyond stage IV, one hip was classified as stage I, and seven were normal.

In the alendronate group, the mean Harris hip score was 65.7 points (range, 34 to 84 points). Seventeen hips were in stage II, and twelve hips were in stage III. Two hips (both in stage III) underwent core decompression at the beginning of the study. On the contralateral side, four hips had already had total hip surgery, three hips were beyond stage IV, one hip was at stage I, and three hips were normal.

#### Radiographic Follow-up

In the control group, twenty of the twenty-five hips had an increase in the Steinberg stage, with nineteen hips having collapsed by the time of the final follow-up. More specifically, of the thirteen hips at stage II at the beginning of the study, three remained at stage II, one progressed to stage III, and nine collapsed. Of the twelve hips at stage III at the beginning of the study, two remained at stage III, and ten collapsed. On the contralateral side, one hip in stage I progressed to stage V.

In the alendronate group, four of the twenty-nine hips progressed one stage or more during the observation period, which was significantly different from the findings in the control group (chi-square test,  $p < 0.001$ ). Of those four hips, two

progressed from stage II to stage III and two progressed from stage III to stage IV (both hips collapsed); these findings were significantly different from those in the control group (chi-square test,  $p < 0.001$ ). On the contralateral side, the three initially normal hips remained normal and one hip progressed from stage I to stage II. No evidence of reduction in or resolution of the necrotic area could be detected by either radiographs or magnetic resonance imaging in any of these osteonecrotic femoral heads.

#### *Surgery and Survival of the Femoral Head*

Seventeen of the twenty-five hips in the control group underwent twenty-one operations (five core decompressions, which were all unsuccessful, and sixteen total hip replacements during the study period), and three of the twenty-nine hips in the alendronate group had four operations (three core decompressions, one of which was unsuccessful, and one total hip replacement); the difference between the groups was significant (chi-square test,  $p < 0.001$ ). Kaplan-Meier survivorship curves, with prosthetic hip replacement as the end point of survival, were generated for both groups (Fig. 1). In the control group, seven hips

had a total hip arthroplasty in the first twelve months and that increased to twelve hips by eighteen months. This contrasts markedly with the alendronate group, in which only one total hip arthroplasty was done at twenty-six months after the initiation of treatment.

#### *Harris Hip Score*

At the end of the study, the mean Harris hip score (and standard deviation) was  $49.2 \pm 9.2$  points (range, 28 to 87 points) in the control group and  $74.4 \pm 7.8$  points (range, 39 to 98 points) in the alendronate group.

#### **Discussion**

Osteonecrosis of the femoral head is a clinical condition with a very complex pathophysiology<sup>13,20</sup>. Because osteonecrosis commonly affects young adults, the economic consequences are often more severe for such patients than they are for individuals with osteoarthritis, who are typically somewhat older. Furthermore, the results after total hip arthroplasty are not as good in patients with osteonecrosis<sup>21</sup>. Any modality that can delay or prevent disease progression would

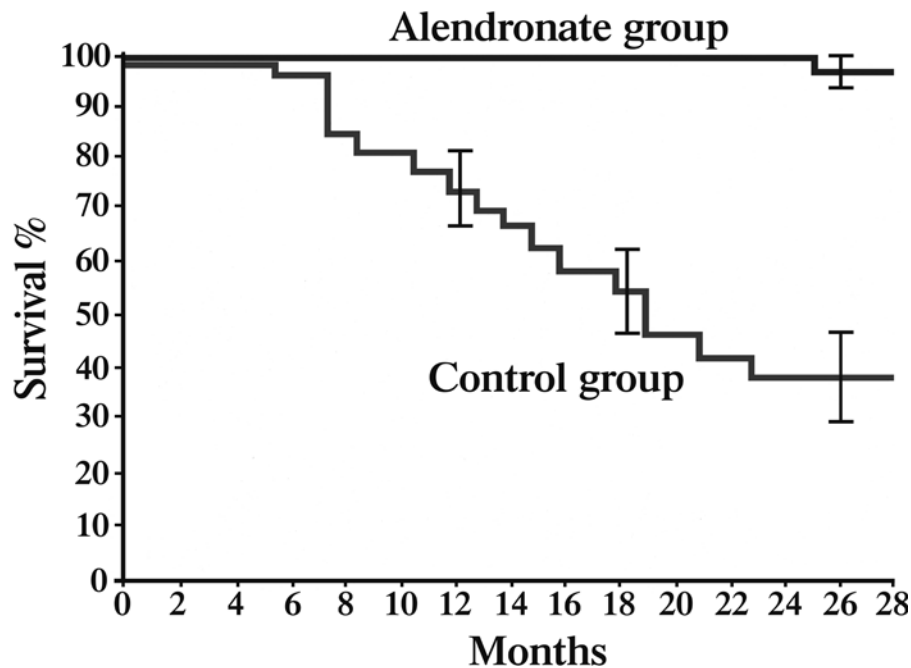


Fig. 1

The Kaplan-Meier survivorship curves, with total hip replacement as the end point, show the survival rate of hips with Steinberg stage-II and stage-III osteonecrosis in the alendronate group and the control group versus observation time. The mean rate of survival of the hips in the alendronate group at twenty-six months was 93.3% (95% confidence interval, 86.9% to 99.7%). The mean rate of survival of the hips in the control group at twelve, eighteen, and twenty-six months was 72% (95% confidence interval, 63% to 81%), 51.8% (95% confidence interval, 42.2% to 61.4%), and 35.8% (95% confidence interval, 25.8% to 45.8%), respectively. At twenty-four months, twenty-nine hips (twenty patients) in the study group and nine hips (seven patients) in the control group had survived. Of the five hips (four patients) in the alendronate group that were observed for twenty-eight months, four hips (three patients) had survived. Of the four hips in the control group that were observed for twenty-eight months, two hips had survived.

be clinically important, particularly in Asian populations, as 40% of the primary total hip arthroplasties in such populations are performed for the treatment of osteonecrosis<sup>2</sup>. It is unknown why certain ethnic Asians are more susceptible. Liberal steroid use is probably a factor. Recent genetic linkage studies have identified mutations in the type-II collagen gene in chromosome 12q13 in a Taiwanese pedigree that strongly predispose to osteonecrosis<sup>22,23</sup>.

Typical findings upon histological examination of a collapsed femoral head include bone necrosis, osteoclastic resorption, and bone regeneration<sup>24</sup>. We do not yet understand the exact mechanism by which osteoclasts act, but a likely mechanism is through absorption of the necrotic bone, which then weakens the structure of the cancellous bone between the viable and the necrotic areas, resulting in multiple microfractures and gross collapse.

Alendronate, a bisphosphonate compound, inhibits the resorptive action of mature osteoclasts. It increases apoptosis of osteoclasts and may reduce apoptosis in osteoblasts and osteocytes<sup>16</sup>, thereby reducing the turnover rate of bone.

In a bone chamber study utilizing a rat model, necrotic bone was not resorbed in the rats treated with alendronate, whereas it was almost entirely resorbed in the controls. The authors concluded that systemic alendronate treatment prevented resorption of necrotic bone during revascularization<sup>25</sup>.

The optimum dosage of alendronate is not known. The dosage regimen used in the present study was chosen because it is the one currently recommended for the treatment of osteoporosis. Astrand and Aspenberg showed in a rat model that reduction of instability-induced bone resorption is dose-dependent<sup>26</sup>. This finding may well apply to the treatment of osteonecrosis, and further study is necessary.


The size of the necrotic area is directly related to the probability of collapse<sup>19,27</sup>. Koo and Kim observed that collapse of Steinberg class-C femoral heads (the focus of this study) usually occurs within the first eighteen months after diagnosis<sup>27</sup>. The survivorship curves in our study show that alendronate prevented or at least delayed the collapse of the femoral head and averted the need for a total hip arthroplasty in the first twenty-four months. However, imaging studies did not demonstrate a reduction in or resolution of the area of necrotic bone.

The present study is not the only one that has found alendronate to be effective. In a recently published study of a noncontrolled case series of sixty patients (100 hips) with osteonecrosis who were treated with alendronate, Agarwala et al. concluded that early surgical intervention could be avoided in most patients<sup>28</sup>.

The limitations of the present study included the small number of patients and the follow-up period of two years, which may have been too short to demonstrate failure. The study was prospective and randomized, but it was only single-blinded radiographically and was not blinded clinically. We were not able to determine the effect of confounding risk factors because of the small numbers. Nevertheless, our preliminary results indicate that alendronate is highly effective, at least in the short term.

We will continue to follow the patients in this study to see whether the short-term results are maintained. Furthermore, a multicenter, double-blind, prospective trial with use of different dosages and durations of alendronate as well as a combination therapy with electric stimulation, shock wave treatment, and alendronate is currently under way.

### Appendix

 Tables presenting patient details for both groups are available with the electronic versions of this article, on our web site at [jbjs.org](http://jbjs.org) (go to the article citation and click on "Supplementary Material") and on our quarterly CD-ROM (call our subscription department, at 781-449-9780, to order the CD-ROM). ■

Kuo-An Lai, MD

Chyun-Yu Yang, MD

Chung-Jung Shao, MD

Jui-Ting Hsu, PhD

Ruey-Mo Lin, MD

Orthopaedic Department (K.-A.L., C.-Y.Y., C.-J.S., and R.-M.L.) and the Institute of Biomedical Engineering (J.-T.H.), National Cheng Kung University Medical Center, No. 138 Shen-Li Road, Tainan, Taiwan. E-mail address for K.-A. Lai: [laikuoan@mail.ncku.edu.tw](mailto:laikuoan@mail.ncku.edu.tw). E-mail address for J.-T. Hsu: [richard@ms32.url.com.tw](mailto:richard@ms32.url.com.tw)

Wun-Jer Shen, MD

Po-Cheng Orthopaedic Institute, 100 Po-Ai 2nd Road, Kaohsiung 81357, Taiwan

The authors did not receive grants or outside funding in support of their research or preparation of this manuscript. They did not receive payments or other benefits or a commitment or agreement to provide such benefits from a commercial entity. A commercial entity (MSD) paid or directed, or agreed to pay or direct, benefits to a research fund, foundation, educational institution, or other charitable or nonprofit organization with which four of the authors are affiliated or associated.

doi:10.2106/JBJS.D.02959

### References

1. Mont MA, Hungerford DS. Non-traumatic avascular necrosis of the femoral head. *J Bone Joint Surg Am.* 1995;77:459-74.
2. Lai YS, Wei HW, Cheng CK. An analysis of hip replacements data of Taiwan. Read at the Northern Region Congress of the Asia Pacific Orthopaedic Association in conjunction with the Third Annual Meeting of the Pacific Asian Society of Minimally Invasive Spine Surgery; 2003 Dec 5-6; Taipei, Taiwan.
3. Steinberg ME. Recent advances in the management of osteonecrosis of the hip. Introduction. *Semin Arthroplasty.* 1998;9:181-3.

4. Reis ND, Schwartz O, Militianu D, Ramon Y, Levin D, Norman D, Melamed Y, Shupak A, Goldsher D, Zinman C. Hyperbaric oxygen therapy as a treatment for stage-I avascular necrosis of the femoral head. *J Bone Joint Surg Br.* 2003;85:371-5.
5. Ludwig J, Lauber S, Lauber HJ, Dreisilker U, Raedel R, Hotzinger H. High-energy shock wave treatment of femoral head necrosis in adults. *Clin Orthop Relat Res.* 2001;387:119-26.
6. Aaron RK, Steinberg ME. Electrical stimulation of osteonecrosis of the femoral head. *Semin Arthroplasty.* 1991;2:214-21.

- 7.** Camp JF, Colwell CW Jr. Core decompression of the femoral head for osteonecrosis. *J Bone Joint Surg Am.* 1986;68:1313-9.
- 8.** Mont MA, Carbone JJ, Fairbank AC. Core decompression versus nonoperative management for osteonecrosis of the hip. *Clin Orthop Relat Res.* 1996;324:169-78.
- 9.** Castro FP Jr, Barrack RL. Core decompression and conservative treatment for avascular necrosis of the femoral head: a meta-analysis. *Am J Orthop.* 2000;29:187-94.
- 10.** Urbaniak JR, Coogan PG, Gunneson EB, Nunley JA. Treatment of osteonecrosis of the femoral head with free vascularized fibular grafting. A long-term follow-up study of one hundred and three hips. *J Bone Joint Surg Am.* 1995;77:681-94.
- 11.** Sugioka Y, Hotokebuchi T, Tsutsui H. Transtrochanteric anterior rotational osteotomy for idiopathic and steroid-induced necrosis of the femoral head. Indications and long-term results. *Clin Orthop Relat Res.* 1992;277:111-20.
- 12.** Inao S, Ando M, Gotoh E, Matsuno T. Minimum 10-year results of Sugioka's osteotomy for femoral head osteonecrosis. *Clin Orthop Relat Res.* 1999;368:141-8.
- 13.** Lieberman JR, Berry DJ, Mont MA, Aaron RK, Callaghan JJ, Rajadhyaksha AD, Urbaniak JR. Osteonecrosis of the hip: management in the 21st century. *Instr Course Lect.* 2003;52:337-55.
- 14.** Cui Q, Wang GJ, Su CC, Balian G. Lovastatin prevents steroid induced adipogenesis and osteonecrosis. *Clin Orthop Relat Res.* 1997;344:8-19.
- 15.** Pritchett JW. Statin therapy decreases the risk of osteonecrosis in patients receiving steroids. *Clin Orthop Relat Res.* 2001;386:173-8.
- 16.** Rodan GA, Fleisch HA. Bisphosphonates: mechanisms of action. *J Clin Invest.* 1996;97:2692-6.
- 17.** Bone HG, Hosking D, Devogelaer JP, Tucci JR, Emkey RD, Tonino RP, Rodriguez-Portales JA, Downs RW, Gupta J, Santora AC, Liberman UA; Alendronate Phase III Osteoporosis Treatment Study Group. Ten years' experience with alendronate for osteoporosis in postmenopausal women. *N Engl J Med.* 2004;350:1189-99.
- 18.** Steinberg ME. Early diagnosis, evaluation, and staging of osteonecrosis. *Instr Course Lect.* 1994;43:513-8.
- 19.** Steinberg ME, Bands RE, Parry S, Hoffman E, Chan T, Hartman KM. Does lesion size affect the outcome in avascular necrosis? *Clin Orthop Relat Res.* 1999;367:262-71.
- 20.** Jones JP Jr. Recent advances in the management of osteonecrosis of the hip. Etiology and pathogenesis. *Semin Arthroplasty.* 1998;9:184-91.
- 21.** Kim YH, Oh SH, Kim JS, Koo KH. Contemporary total hip arthroplasty with and without cement in patients with osteonecrosis of the femoral head. *J Bone Joint Surg Am.* 2003;85:675-81.
- 22.** Chen WM, Liu YF, Lin MW, Chen IC, Lin PY, Lin GL, Jou YS, Lin YT, Fann CS, Wu JY, Hsiao KJ, Tsai SF. Autosomal dominant avascular necrosis of femoral head in two Taiwanese pedigrees and linkage to chromosome 12q13. *Am J Hum Genet.* 2004;75:310-7.
- 23.** Liu YF, Chen WM, Lin YF, Yang RC, Lin MW, Li LH, Chang YH, Jou YS, Lin PY, Su JS, Huang SF, Hsiao KJ, Fann CS, Hwang HW, Chen YT, Tsai SF. Type II collagen gene variants and inherited osteonecrosis of the femoral head. *N Engl J Med.* 2005;352:2294-301.
- 24.** Bauer TW, Plenk H Jr. The pathology of early osteonecrosis of the femoral head. *Semin Arthroplasty.* 1998;9:192-202.
- 25.** Astrand J, Aspenberg P. Systemic alendronate prevents resorption of necrotic bone during revascularization. A bone chamber study in rats. *BMC Musculoskelet Disord.* 2002;3:19.
- 26.** Astrand J, Aspenberg P. Reduction of instability-induced bone resorption using bisphosphonates: high doses are needed in rats. *Acta Orthop Scand.* 2002;73:24-30.
- 27.** Koo KH, Kim R. Quantifying the extent of osteonecrosis of the femoral head. A new method using MRI. *J Bone Joint Surg Br.* 1995;77:875-80.
- 28.** Agarwala S, Jain DK, Joshi VR, Sule A. Efficacy of alendronate, a bisphosphonate, in the treatment of AVN of the hip. A prospective open-label study. *Rheumatology (Oxford).* 2005;44:352-9. Erratum in: *Rheumatology (Oxford).* 2005;44:569.